



## Evaluating the Changes in Soft Tissue Profile and Masseter Muscle Associated with Early Treatment of Anterior Crossbite in Children

### Çocuklarda Görülen Anterior Çapraz Kapanışların Erken Tedavileri Sonucunda Yumuşak Doku Profiline ve Masseter Kasında Görülen Değişikliklerin İncelenmesi

Handan Çelik<sup>1</sup>, Esin Alpöz<sup>2</sup>, Abdulhalim Aysel<sup>3</sup>, Özüm Daşdemir<sup>4</sup>, Fahinur Ertuğrul<sup>5</sup>, Gülcan Coşkun Akar<sup>6</sup>, Sercan Göde<sup>7</sup>, Arzu Aykut Yetkiner<sup>5</sup>, Nazan Ersin<sup>5</sup>

<sup>1</sup>İzmir Democracy University Faculty of Dentistry, Department of Pediatric Dentistry, İzmir, Turkey

<sup>2</sup>Ege University Faculty of Dentistry, Department of Oral and Maxillofacial Radiology, İzmir, Turkey

<sup>3</sup>University of Health Sciences Turkey, İzmir Bozyaka Education and Research Hospital, Department of Otolaryngology, İzmir, Turkey

<sup>4</sup>Kütahya Health Sciences University Faculty of Dentistry, Department of Orthodontics, Kütahya, Turkey

<sup>5</sup>Ege University Faculty of Dentistry, Department of Pediatric Dentistry, İzmir, Turkey

<sup>6</sup>Ege University Faculty of Dentistry, Department of Prosthodontics, İzmir, Turkey

<sup>7</sup>Ege University Faculty of Medicine, Department of Otolaryngology, İzmir, Turkey

#### Abstract

**Objective:** This study aimed to evaluate the effects of a removable mandibular retractor appliance on the soft tissue profile and masseter muscle as an early intervention tool in children with anterior crossbite and the impact of this malocclusion on patient quality of life.

**Materials and Methods:** The participants underwent cephalometric radiography for soft tissue measurement and ultrasonography for masseter muscle measurement before and after using a mandibular retractor appliance.

**Results:** SN-GoMe, Max1-SN, Max1-NA, Max1-Na, and Ls-E values, increased and decreased in the inter-incisor mandibular plane angle in the 18 children who completed the 12-month treatment. Ultrasonographic evaluation of the masseter muscle demonstrated that the thickness of the muscle increased both at rest and during contraction.

**Conclusion:** The regular use of the removable mandibular retractor appliance in individuals during growth directs the mandible downward and posteriorly, stimulates the anterior growth of the maxilla, and provides a treatment for anterior crossbite.

**Keywords:** Anterior crossbite, cephalometric hard tissue changes, soft tissue changes, masseter, treatment

#### Öz

**Amaç:** Bu çalışmada, ön çapraz kapanışı olan çocuklarda erken müdahale olarak hareketli mandibular retraksiyon apareyinin yumuşak doku profili ve masseter kası üzerine etkileri ve bu maloklüzyonun hastaların yaşam kalitesine etkilerinin değerlendirilmesi amaçlanmıştır.

**Gereç ve Yöntemler:** Katılımcılara mandibular retraksiyon apareyi kullanıldı. Tedavi öncesi ve tedavi sonrasında yumuşak doku profil değerlendirilmesi, sefalometrik radyografik değerlendirme ve masseter kasının ultrasonografi değerlendirilmesiyle ölçümleri yapıldı.

**Bulgular:** On iki aylık tedaviyi tamamlayan 18 çocukta SN-GoMe, Max1-SN, Max1-NA, Max1-Na ve Ls-E değerlerinde anlamlı bir artış ve mandibular düzlem ile alt orta kesici dişin uzun eksen arasında kalan açı değeri ise düşüş gösterdi. Masseter kasının ultrasonografik değerlendirmesi, kas kalınlığının hem istirahatte hem de kasılma sırasında arttığını gösterdi.

**Sonuç:** Bireylerde büyüme sırasında hareketli mandibular retraksiyon apareyinin düzenli kullanımı mandibulayı aşağıya ve posteriora yönlendirir, maksillanın anterior büyümesini uyarır ve anterior çapraz kapanışın tedavisini sağlar.

**Anahtar Kelimeler:** Ön çapraz kapanış, sefalometrik sert doku değişiklikleri, yumuşak doku değişiklikleri, masseter, tedavi

**Address for Correspondence/Yazışma Adresi:** Lect. Handan Çelik, MD, İzmir Democracy University Faculty of Dentistry, Department of Pediatric Dentistry, İzmir, Turkey

**Phone:** +90 553 709 96 15 **E-mail:** dthandancelik@gmail.com

**ORCID ID:** orcid.org/0000-0002-5642-4641

**Received/Geliş Tarihi:** 26.09.2022

**Accepted/Kabul Tarihi:** 04.12.2023



## Introduction

Angle described class III malocclusion as the anterior position of the lower jaw, mesial occlusion of the lower teeth, and the lingual inclination of the lower incisors (1). Class III malocclusions are easy to diagnose but are quite difficult to treat. Moreover, there are differences of opinion in the literature regarding the best timing for treatment (2). Studies addressed the timing aspect acknowledge that the treatment should begin as soon as possible after the condition is diagnosed (3). Previously, studies reported that if not promptly treated, class III malocclusions diagnosed in the early stages may be detrimental to the physical and mental development of the child (4-6). The early treatment of functional and dental anterior crossbite cases (functional class III malocclusions) is highly recommended, particularly in children (7). If not treated early enough, functional anomalies may deteriorate into morphological anomalies, thus making them much more complicated to treat (8,9). Treatment options for class III malocclusions vary depending on the age of the individual and the origin of the malocclusion. The primary treatment method in children of developmental age is to direct the growth using various removable appliances (10). The hypothesis of this study is to reduce skeletal deviance and to provide a better environment for normal growth, to ensure harmonious growth of the mandible and maxilla as much as possible, to prevent functional malocclusion from turning into a skeletal problem, to improve occlusal relationship, to improve facial aesthetics by correcting soft tissue aesthetics, and to improve facial aesthetics for the patient. It is envisaged to provide a psychosocial development. This study sought to examine the effectiveness of a removable mandibular retractor appliance as an early intervention tool to reduce future problems in children aged 7-10 years with a functional or dental anterior crossbite, as well as changes in the soft tissue profile and masseter muscle. Secondly, this study aimed to explore the impacts of problems associated with class III malocclusions on the quality of life (QoL) and psychosocial development of the patients.

## Materials and Methods

### Participants

This study comprised 20 children aged 7-10 years with functional or dental anterior crossbite who was admitted to a clinic for routine check-ups or other dental treatments. None of the participants had mental illness or familial prognathism. They had symmetrical condylar growth and anterior crossbite, and they were cooperative. Two of the patients were excluded as they discontinued the treatment. The 18 patients with

anterior crossbite underwent oral examinations. First, patients were checked if their lower incisor edges occlude with the edges of the upper central incisors to ascertain the type of the malocclusion, i.e., functional or skeletal. Cephalometric analyzes of the patients included in the study were performed before and after treatment. Photographs and soft tissue analyzes were performed before and after the treatment. To control the development of the masseter muscle, ultrasound images of the masseter muscle were taken before and after the treatment. For the correction of anterior crossbite, a mandibular retraction appliance was planned by taking measurements from the patients, and the appliance was requested to be used for a total of 1 year by being called for control every month for 12 months. In order to investigate the effect of oral health on QoL, a questionnaire was conducted before and after the treatment. The study was approved by the Ethics Committee of Ege University Clinical Research Ethics Committee (decision no: 18-2/32, date: 13.02.2018). All participants of this study voluntarily consented to participate, reading and signing the informed consent term.

### Data Collection Tools

#### Cephalometric Evaluation

Initial and final lateral cephalometric radiographs of the patients were obtained at Ege University Faculty of Dentistry, Department of Oral and Maxillofacial Radiology. Digital cephalometric analyses were performed using VistaDent® (VistaDent-Dentsply GAC, Chicago, IL, USA).

#### Evaluation of Changes in Soft Tissue

Changes in facial soft tissues were evaluated using Rhinobase, facial analysis, and picture-archiving software developed by Ege University Faculty of Medicine, Department of Otorhinolaryngology. Pre- and post-treatment frontal and lateral facial images of the patients were taken at Ege University Faculty of Medicine, Department of Otorhinolaryngology. The calibration of images and soft tissue analyses were performed using Rhinobase.

#### Ultrasonographic Evaluation of the Masseter Muscle

Ultrasonographic imaging of the patients' masseter muscles was performed at the Department of Oral and Maxillofacial Radiology with Hitachi Aloka F37 Diagnostic Ultrasound System Aloka Medical Ltd., Tokyo, Japan) ultrasound imaging device. All measurements were done on right and left masseter regions, using a high-frequency (13-5 MHz) linear probe both at rest position and contraction. The ultrasound probe was placed parallel to the occlusal plane, perpendicular to the muscle surface, and transversely 2.5 cm above the inferior mandibular border with the patient at the supine position. The thickness of the masseter muscle was measured parallel to the outer fascia of the muscle and

the lateral surface of the ramus. The measurements were performed both before and after the treatment.

### Measuring the Effects of Oral Health on Quality of Life

Participants were asked to fill in the "Effects of Oral Health on Quality of Life Questionnaire" both before and after the treatment to examine the child's oral health-related quality of life (OHRQoL). The two generic questions in the first part of the questionnaire were related to the children's perception of the state of their oral health and its effects on their QoL.

### Removable Mandibular Retractor Appliance and its Use

Removable mandibular retractor appliances were used for treating patients participating in the study. Unlike the common practice, the vestibular arch used in the anterior region was designed to pass through the vestibular parts of the mandibular anterior teeth. The wire passing through the vestibular parts of these lower teeth was bent using 0.9 mm stainless steel wire. The loops of the vestibular arch were bent to pass through the vestibular parts of the lower canine teeth to prevent the mandible from moving forward under force during function. The Bertoni screw fitted to the appliance was aimed at achieving both sagittal and transverse expansion. The patients used the appliance every day for at least 18 h including sleeping hours. The patients were instructed to activate the expansion screw by rotating it for a full turn once a week in the direction marked in the palatal area of the appliance. Patients returned for a second visit after 2 weeks and adjustments were made for a better fit. Patients were called for routine follow-ups once every month during the 12-month therapy and additional adjustments were made to improve the fit of the appliances. Intraoral view before and after the treatment (Figure 1).

### Statistical Analysis

Shapiro-Wilk normality test was used to determine the compliance of the variables to normal distribution. The comparison of median values of numerical variables that are not normally distributed was compared using the Wilcoxon

test. McNemar's test was used for pre-treatment and post-treatment analysis of dichotomous categorical variables, and McNemar-Bowker test was used for pre-treatment and post-treatment analysis of categorical variables with more than two probabilities. Values with a p-value of  $<0.05$  were considered statistically significant. For all statistical analysis SPSS Statistics Ver. 22.0 (SPSS Inc. Chicago, IL, USA) was used.

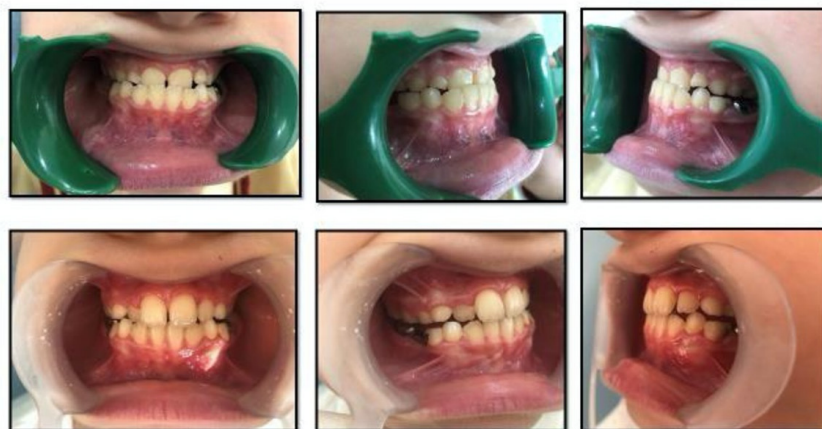## Results

### Cephalometric Findings

This study comprised 20 children aged 7-10 years with a functional or dental anterior crossbite. Two of the patients were excluded as they discontinued the treatment. The cephalometric analysis of the results from the 18 patients before and after the treatment exhibited statistically significant differences in the values for SNGoMe, Max1-SN, Max1-NA, Max1-Na, inter-incisor mandibular plane angle (IMPA), Ls-E (respective p-values: 0.002; 0.022; 0.037; 0.005; 0.013; 0.016) (Table 1). However, there was no statistically significant difference in the values of Sella, Nasion, A-point, Sella, Nasion, B-point, A-point, Nasion, B-point, Wits, frankfor mandibular angle, Mand1-NB, Mand1-NB, Interincisal, LI-E, Nasolabial and Convexity (respective p-values: 0.619; 0.981; 0.740; 0.339; 0.054; 0.463; 0.614; 0.155; 0.290; 0.255; 0.795) (Table 1).

### Soft Tissue Findings

Analysis of the data from the soft tissue measurements of the patients before and after the treatment exhibited statistically significant differences in the values for the lower facial height, lower labial length, the vertical length of the chin, nasomental angle, convexity angle, and mentolabial sulcus depth (respective p-values: 0.004; 0.002; 0.007; 0.001; 0.010 and 0.009). Data showed no statistically significant difference in the values for upper facial height, mid-facial height, and nasolabial angle (respective p-values: 0.379; 0.277 and 0.460) (Table 2).



**Figure 1.** Intraoral view before and after the treatment

**Table 1. Comparison of pre- and post-treatment cephalometric measurements**

	Pre-treatment		Post-treatment		p-value
	Mean ± SD	Median (min-max)	Mean ± SD	Median (min-max)	
SNA	79.36±4.20	78.3 (72.2-87.6)	79.0±4.17	80 (71.6-84)	0.619
SNB	77.90±3.66	76.85 (71.7-83.3)	77.54±4.0	76.65 (71-84)	0.981
ANB	1.46±2.39	1.5 (-3.3-5.1)	1.47±2.22	1.10 (-1.7-6.4)	0.740
Wits	-3.39±2.32	-3 (-7-1)	-3.83±2.81	-4.5 (-9-0)	0.339
FMA	26.33±9.11	25.5 (14-59)	27.28±4.44	27.5 (19-35)	0.054
SNGoMe	34.50±5.54	34.5 (25-44)	37.22±5.56	37 (27-46)	0.002**
Max1-SN	99.68±6.52	100.35 (88.3-112.4)	103.54±6.02	103.65 (92.9-113.5)	0.022*
Max1-NA	20.32±6.73	21.40 (8.8-29.4)	24.44±4.71	24.75 (13-31.2)	0.037*
Max1-Na	1.61±1.29	1 (0-4)	3.0±1.78	4 (0-5)	0.005**
IMPA	89.72±5.45	89 (83-104)	86.83±5.22	87 (79-97)	0.013*
Mand1-NB	22.92±4.50	22.6 (12.4-31.5)	21.71±4.95	22.7 (11.1-28.7)	0.463
Mand1-NB (mm)	3.83±1.20	4 (2-6)	3.61±1.33	4 (1-6)	0.614
Interincisal angle	134.5±9.17	134 (119-156)	132.39±6.83	131.5 (123-147)	0.155
Ls-E	-4.11±2.35	-4 (-8-1)	-2.94±1.73	-3 (-6-1)	0.016*
LI-E	-0.56±2.35	0 (-5-3)	0.16±1.95	0.5 (-4-3)	0.290
Nasolabial angle	107.4±14.9	108 (85-134)	111.4±10.82	112 (92-141)	0.255
Convexity angle	-8.61±6.0	-8.5 (-21- -1)	-9.33±6.15	-9.5 (-22- -1)	0.795

\*p<0.05, \*\*p<0.01, SD: Standard deviation, min-max: Minimum-maximum, SNA: Sella, Nasion, A-point, SNB: Sella, Nasion, B-point, ANB: A-point, Nasion, B-point, FMA: Frankfor mandibular angle, IMPA: Inter-incisor mandibular plane angle, min-max: Minimum-maximum

**Table 2. Comparison of pre- and post-treatment soft tissue measurements**

	Pre-treatment		Post-treatment		p-value
	Mean ± SD	Median (min-max)	Mean ± SD	Median (min-max)	
Upper facial height	54.0±6.23	54.05 (44.9-66.4)	52.10±6.10	53 (39.8-60.9)	0.379
Mid-facial height	51.47±3.72	51.9 (43.6-56.1)	50.0±4.61	49.2 (43.6-61.7)	0.277
Lower facial height	50.77±6.58	49.85 (40.1-67.1)	56.3±5.70	55.1 (44.1-67.2)	0.004**
Upper labial height	14.6±1.60	14.65 (11.8-17.9)	16.7±1.65	16 (13.2-19.7)	0.002**
Vertical length of the chin	30.81±5.28	29.5 (23.5-42.4)	35.6±5.36	35.1 (23.5-46.7)	0.007**
Nasolabial angle	123.9±18.9	120.5 (90-172)	121.5±16.48	120 (90-157)	0.460
Nasomental angle	131.5±7.66	128.5 (122-147)	137.28±6.87	137.5 (128-153)	0.001**
Convexity angle	18.61±7.27	17.5 (5-36)	15.5±4.13	15.5 (8-23)	0.010*
Mentolabial sulcus depth	1.72±1.44	1.25 (0.10-5)	2.70±1.80	2.35 (0.50-6.60)	0.009**

\*p<0.05, \*\*p<0.01, SD: Standard deviation, min-max: Minimum-maximum

### Masseter Muscle Findings

The data collected from the measurements of the masseter muscle thickness before and after treatment showed a statistically significant increase in the muscle thicknesses on both right and left at rest and contraction (Table 3, Figure 2). However, there was no significant change in the right

and left masseter muscle types of the patients before and after the treatment.

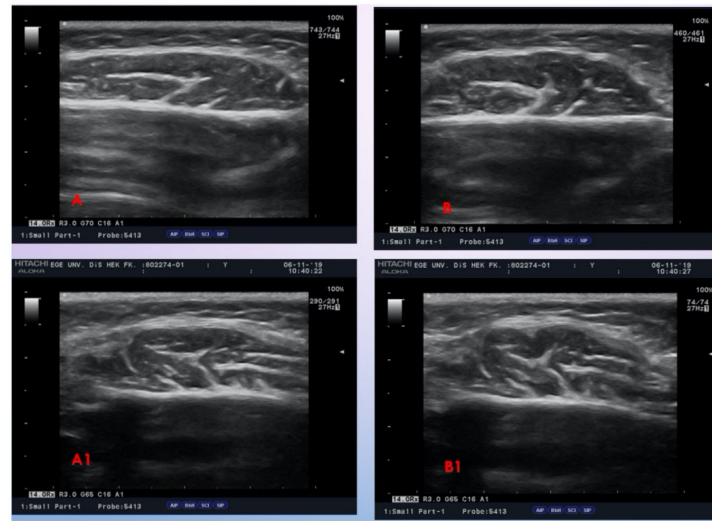
### The Effect of Oral Health on Quality of Life

In the first part of the "Effects of Oral Health on Quality of Life Questionnaire", the participants were asked to

Table 3. Comparison of pre- and post-treatment measurements of masseter muscle thickness

	Pre-treatment		Post-treatment		p-value
	Mean $\pm$ SD	Median (min-max)	Mean $\pm$ SD	Median (min-max)	
Right at rest	0.74 $\pm$ 0.15	0.72 (0.55-1.07)	0.83 $\pm$ 0.16	0.82 (0.55-1.14)	0.001**
Right at cont.	0.99 $\pm$ 0.18	1.03 (0.68-1.34)	1.06 $\pm$ 0.18	1.1 (0.78-1.39)	0.012*
Left at rest	0.75 $\pm$ 0.13	0.74 (0.51-0.94)	0.86 $\pm$ 0.17	0.90 (0.58-1.13)	<0.001***
Left at cont.	0.97 $\pm$ 0.16	0.97 (0.67-1.24)	1.08 $\pm$ 0.17	1.1 (0.72-1.36)	0.002**

\*p<0.05, \*\*p<0.01, \*\*\*p<0.001, Cont.: Contraction, SD: Standard deviation, min-max: Minimum-maximum



**Figure 2.** A) Initial image of the patient in the resting position, B) Initial view of the patient in the contraction position, A1) Post-treatment image of the patient in the resting position, B1) Post-treatment image of the patient in the contraction position

respond to the question. The OHRQoL survey used in this study produced a mean total survey score of 40.33 $\pm$ 14.94 before the treatment, and the post-treatment figure was 35.89 $\pm$ 12.32. The drop in the mean total survey score was not statistically significant (p=0.193). No statistically significant difference was reported between the pre-and post-treatment sub-group to mean scores of intraoral findings, functional limitation, emotional well-being, and social well-being (respective p-values: 0.242; 0.253; 0.243; 0.062).

## Discussion

This study examined the effects of a removable mandibular retractor appliance as an early intervention tool on the soft tissue profile and masseter muscle in children aged 7-10 years with a functional or dental anterior crossbite, and the impacts of the problems associated with this malocclusion on patients' QoL and psychosocial development. There are different opinions in the literature regarding the best treatment timing and treatment modality in children with Class III malocclusion. Woon and Thiruvengkatachari (11) argued that early treatment should be performed before

the age of 10 to maximize bone manipulation while other studies reported that treatment should be initiated as soon as the condition is diagnosed (12-14). Salzmann (3) reported that treatment should be started as soon as class III malocclusion is diagnosed. According to Ülgen (8), when the symptoms of functional anterior crossbite are first noticed, it is possible to treat it in a simpler and shorter time. If untreated, in the case of crossbite, the temporomandibular joint as a result of bone development that may occur, the mandible cannot be pushed posteriorly will come (13). Another issue discussed in the literature and tried to be explained by growth-development studies is how the class III structure takes shape as the individual grows. Does the anomaly get worse over time? According to previous studies reported that class III structure progresses with age and becomes more serious (15-17). Mitani (18) compared 18 untreated Japanese patients with prognathic mandibles with 22 untreated class I cases. He reported that the amount of growth was similar until puberty, and changed in the following period. In addition to its advantages such as easy removal and better patient adaptation because of its smaller size, there are certain disadvantages such as patient compliance and the patient's level of cooperation in using the



appliance, which affect the success of the treatment (19). In our study, we observed that the regular use of a removable mandibular retractor appliance for an average period of 12 months was effective in correcting anterior crossbite. Digital cephalometric analysis done using VistaDent® demonstrated that the increase in the SnGoMe angle was significant in patients who regularly used the mandibular retractor appliance, indicating that the mandibular growth was directed downward and posteriorly. The vestibular arch of the appliance passing through the anterior part of the mandible is believed to have contributed to this orientation. The results of our study showed a decrease in IMPA value, which indicates the retrusion of the mandibular central incisors. The cephalometric analysis detected an increase in the Max1-SN value. It was observed that the Bertoni screw located in the palatal area of the appliance helped the maxillary anterior teeth protrude. Previously, studies reported that an increase in the Ls-E value is notable as the maxillary anterior teeth achieve a labial movement, and the upper lip moves forward significantly with better lip support and a corrected crossbite. Our study reported similar results, which indicated that the normal position of the lips was related to the movement of the central teeth in the anterior region and that the upper lip came forward with the transition of the maxillary anterior teeth from crossbite to normal bite (20). Masseter muscle completes its development both in terms of structure and thickness in adulthood. When the muscle contracts, it lifts the mandible upwards, allowing the teeth to close. This feature makes masseter a very effective muscle in mastication. The superficial fibers of the masseter muscle help push the mandible forward (21). In our study, the internal fibrillar structure of the masseter muscle was evaluated ultrasonographically in individuals with an anterior crossbite. To our knowledge, there is a limited number of studies in the literature evaluating the thickness of the masseter muscle in children, and up to date, no study has examined the fibrillar structure of the muscle in children (22). Correction of malocclusions influences self-esteem and the QoL in pediatric patients (23,24). Accordingly, there was a decrease in the total scores obtained from the questionnaires applied before the treatment and the total scores obtained from the questionnaires after the treatment. This outcome can be explained by the improvement in children's QoL with the correction of the malocclusion. In conclusion, this study reported that the regular use of the mandibular retractor appliance prevents the excess mandibular growth and stimulated the anterior expansion of the maxilla, as well as eliminated anterior crossbite in children aged 7-10 years with a functional or dental anterior crossbite. Moreover, we observed a reduction in the OHRQoL scores of the patients after the treatment.

## Conclusion

In patients who regularly use the mandibular retractor appliance, anterior crossbite improved in a short period and

the appliance contributed to the downward and posterior movement of the mandible by directing the mandibular growth. There was a significant increase in lower facial height when evaluating facial soft tissue measurements. The convexity angle was reduced to the soft tissue profile, enabling a flatter profile. In most patients, the position of the upper lip was positively affected, and the profile was improved. Moreover, there was a significant increase in the length of the upper lip. The ultrasonographic evaluation of the masseter muscle demonstrated an increase in its thickness at both rest and contraction. The study reported that malocclusions adversely affected the OHRQoL of the children and that the correction of the malocclusion had positive psychological effects. Mandibular retractor appliance provides changes in both hard tissue and soft tissue in a short period in cooperative children. Future studies will be useful to further investigate the appliance's effects.

## Acknowledgements

This study was produced from the PhD program graduation thesis of Ege University Faculty of Dentistry, Department of Pedodontics.

## Ethics

**Ethics Committee Approval:** The study was approved by the Ethics Committee of Ege University Clinical Research Ethics Committee (decision no: 18-2/32, date: 13.02.2018).

**Informed Consent:** All participants of this study voluntarily consented to participate, reading and signing the informed consent term.

## Authorship Contributions

Surgical and Medical Practices: H.Ç., E.A., A.A., Ö.D., A.A.Y., N.E., Concept: H.Ç., Ö.D., F.E., G.C.A., S.G., N.E., Design: H.Ç., A.A., F.E., G.C.A., A.A.Y., N.E., Data Collection or Processing: H.Ç., E.A., A.A., Ö.D., N.E., Analysis or Interpretation: H.Ç., E.A., A.A., F.E., S.G., N.E., Literature Search: H.Ç., Ö.D., S.G., N.E., Writing: H.Ç., E.A., N.E.

**Conflict of Interest:** No conflict of interest was declared by the authors.

**Financial Disclosure:** This study was partially funded by the Ege University Scientific Research Projects Coordination ID no: 234, project no: 18-DİŞ-010.

## References

- Gündüz Arslan S, Devcioğlu Kama J. Early treatment of skeletal Class III anomalies: (case report). *Turk J Orthod* 2004; 17: 89-98.
- Turley PK. Treatment of the Class III malocclusion with maxillary expansion and protraction. *Semin Orthod* 2007; 13: 143-57.
- Salzmann JA. Practice of Orthodontics. Philadelphia and Montreal: JB Lippincott Company; 1966.
- Baccetti T, Franchi L, McNamara JA Jr. Treatment and posttreatment craniofacial changes after rapid maxillary expansion and facemask therapy. *Am J Orthod Dentofacial Orthop* 2000; 118: 404-13.

5. Campbell PM. The dilemma of Class III treatment. Early or late? *Angle Orthod* 1983; 42: 175-91.
6. Guyer EC, Ellis EE 3rd, McNamara JA Jr, Behrents RG. Components of class III malocclusion in juveniles and adolescents. *Angle Orthod* 1986; 56: 7-30.
7. Fleming PS. Timing orthodontic treatment: early or late? *Aust Dent J* 2017; 62(Suppl): 11-9.
8. Ülgen M. Anomaliler, sefalometri, Etiyoloji, Büyüme ve Gelişim, Tanı. 2. Baskı. İstanbul, T.C Yeditepe Üniversitesi Yayınları, 2000.
9. Proffit WR, Fields Jr HW, Sarver DM. The orthodontic problem. *Contemporary Orthodontics*. 2014.
10. Chang HP, Tseng YC, Chang HF. Treatment of mandibular prognathism. *J Formos Med Assoc* 2006; 105: 781-90.
11. Woon SC, Thiruvengkatachari B. Early orthodontic treatment for Class III malocclusion: A systematic review and meta-analysis. *Am J Orthod Dentofacial Orthop* 2017; 151: 28-52.
12. Ngan P, Moon W. Evolution of Class III treatment in orthodontics. *Am J Orthod Dentofacial Orthop* 2015; 148: 22-36.
13. Ülgen M. Ortodontik Tedavi Prensipleri. 4. baskı." İstanbul: Dilek-Örümç Matbaası; 1993.
14. Fränkel R. Maxillary retrusion in Class 3 and treatment with the function corrector 3. *Rep Congr Eur Orthod Soc* 1970: 249-59.
15. Dietrich UC. Morphological variability of skeletal Class 3 relationships as revealed by cephalometric analysis. *Rep Congr Eur Orthod Soc* 1970: 131-43.
16. Jacobson A, Evans WG, Preston CB, Sadowsky PL. Mandibular prognathism. *Am J Orthod* 1974; 66: 140-71.
17. Mitani H, Sato K, Sugawara J. Growth of mandibular prognathism after pubertal growth peak. *Am J Orthod Dentofacial Orthop* 1993; 104: 330-6.
18. Mitani H. Prepubertal growth of mandibular prognathism. *Am J Orthod* 1981; 80: 546-53.
19. Akın M, Tezcan M, İleri Z. Comparison of conventional and digital cephalometric measurement methods. *Suleyman Demirel University Journal of Health Sciences* 2014; 5: 94-7.
20. Kiliçoğlu H, Kirliç Y. Profile changes in patients with class III malocclusions after Delaire mask therapy. *Am J Orthod Dentofacial Orthop* 1998; 113: 453-62.
21. Şakul B. Baş ve Boyun Topografik Anatomisi. 1. Baskı, Ankara Üniversitesi Basımevi; 1999.
22. Patini R, Gallenzi P, Lione R, Cozza P, Cordaro M. Ultrasonographic Evaluation of The Effects of Orthodontic or Functional Orthopaedic Treatment on Masseter Muscles: A Systematic Review and Meta-Analysis. *Medicina (Kaunas)* 2019; 55: 256.
23. Lione R, Kiliaridis S, Noviello A, Franchi L, Antonarakis GS, Cozza P. Evaluation of masseter muscles in relation to treatment with removable bite-blocks in dolichofacial growing subjects: A prospective controlled study. *Am J Orthod Dentofacial Orthop* 2017; 151: 1058-64.
24. Shaw B. Uncertainty of orthodontic benefit and the questionable ethics of marketing. In *Seminars in Orthodontics*, WB Saunders; 2012; 18: 210-6.