

# Investigation of Metacarpal Bone Morphology in Normal-weight, Overweight and Obese Adolescent Subjects

*Normal Kilolu, Aşırı Kilolu ve Obez Adölesan Bireylerde Metakarpal Kemik Morfolojisinin İncelenmesi*

✉ Yasemin Nur Korkmaz<sup>1</sup>, ✉ Süleyman Kutalmış Büyük<sup>2</sup>, ✉ Hüseyin Şimşek<sup>3</sup>

<sup>1</sup>Bolu Abant İzzet Baysal University Faculty of Dentistry, Department of Orthodontics, Bolu, Turkey

<sup>2</sup>Ordu University Faculty of Dentistry, Department of Orthodontics, Ordu, Turkey

<sup>3</sup>Ordu University Faculty of Dentistry, Department of Pediatric Dentistry, Ordu, Turkey



## Keywords

Bone, growth, obesity, radiography

## Anahtar Kelimeler

Kemik, büyüme, obezite, radyografi

Received/Geliş Tarihi : 28.08.2018

Accepted/Kabul Tarihi : 11.01.2019

doi:10.4274/meandros.galenos.2019.93063

## Address for Correspondence/Yazışma Adresi:

Yasemin Nur Korkmaz DDS,  
Bolu Abant İzzet Baysal University Faculty of  
Dentistry, Department of Orthodontics, Bolu,  
Turkey  
Phone : +90 374 253 45 00-85 10  
E-mail : dtyaseminnurkorkmaz@gmail.com

ORCID ID: orcid.org/0000-0003-2261-6925

©Meandros Medical and Dental Journal, Published by  
Galenos Publishing House.  
This is article distributed under the terms of the  
Creative Commons Attribution NonCommercial 4.0  
International Licence (CC BY-NC 4.0).

## Abstract

**Objective:** The prevalence of childhood and adolescent overweight and obesity is increasing in most developed countries. This study aimed to investigate the metacarpal bone morphology in normal-weight, overweight and obese adolescent subjects at different pubertal stages.

**Materials and Methods:** This radiographic study was performed in 124 subjects at different pubertal stages. The subjects were divided into three groups based on body mass index percentile: normal-weight, overweight and obese. The second and fourth metacarpal bone cortical thickness, width and metacarpal index (MCI) were measured on left hand-wrist radiographs.

**Results:** The values of the second and fourth metacarpal bone cortical thickness and width were significantly different among the groups. The second metacarpal bone MCI was significantly different among the groups. Moreover, the values of the second and fourth metacarpal bone cortical thickness, width and MCI in obese and overweight subjects were greater than those in normal-weight subjects. The values of the second and fourth metacarpal bone cortical thickness and width were significantly different in subjects before and after their pubertal growth peak period.

**Conclusion:** The metacarpal bone parameter in overweight and obese adolescent subjects was significantly greater than that in normal-weight subjects.

## Öz

**Amaç:** Gelişmiş ülkelerde çocuk ve adölesanlarda aşırı kilo ve obezite prevalansı artmaktadır. Bu çalışmanın amacı, farklı pubertal dönemlerde normal kilolu, aşırı kilolu ve obez adölesanlarda metakarpal kemik morfolojisini araştırmaktır.

**Gereç ve Yöntemler:** Bu radyografik çalışmaya, farklı pubertal aşamalarda 124 birey dahil edildi. Olgular vücut kitle indeksi yüzdesine göre normal kilolu, fazla kilolu ve obez bireyler olmak üzere üç gruba ayrıldı. Sol el-bilek radyografilerinde ikinci ve dördüncü metakarpal kemiklerde kortikal kalınlık, genişlik ve metakarpal indeks (MKİ) ölçümleri yapıldı.

**Bulgular:** İkinci ve dördüncü metakarpal kemiklerde kortikal kalınlık ve genişlik gruplar arasında anlamlı olarak farklı bulundu. Gruplar arasında ikinci metakarpal kemik MKİ'de anlamlı bir fark tespit edildi. İkinci ve dördüncü metakarpal kemiğin kortikal kalınlığı, genişliği ve MKİ değerleri obez ve fazla kilolu bireylerde, normal kilolu bireylere göre daha yüksekti. Pubertal büyüme atılımı öncesi ve sonrasında ikinci ve dördüncü metakarpal kemiğin kortikal kalınlık ve genişlik değerlerinde anlamlı farklılıklar bulundu.

**Sonuç:** Aşırı kilolu ve obez adolesan bireylerde, normal kilolu bireylere göre anlamlı derecede daha yüksek metakarpal kemik parametresi bulunmaktadır.

## Introduction

Obesity prevalence is increasing rapidly and it is one of the most widespread metabolic diseases in developed countries. The terms overweight and obesity are defined as a condition of abnormal or excessive fat accumulation in adipose tissue at a level that could damage health. It is related to excess food consumption, poor dietary intake, and insufficient physical activity. According to the World Health Organization, childhood obesity is one of the most important health problems due to its rapid rate of increase. Obesity development in childhood is associated with the following obesity in adulthood (1).

Body mass index (BMI) is a convenient and easy way of classifying obesity and overweight. It is formulated as the weight (kilogram) divided by the square of height (meters) (2). However, BMI is not as reliable in childhood because of the growth potential of the patient which enhances BMI through the growth of fat-free tissues (3). BMI percentile which is age and gender-specific is essential to provide a correct classification of BMI in childhood, and it is referred to as BMI-for-age (4). According to this classification, BMI under the 5<sup>th</sup> percentile describes underweight, BMI between 5<sup>th</sup>-84<sup>th</sup> percentile describes normal, BMI between 85<sup>th</sup>-94<sup>th</sup> percentile describes overweight and BMI upper 95<sup>th</sup> percentile describes obese (5).

The effect of obesity on the skeletal system has been a topic of interest in the literature. Mechanical loading caused by increased body weight in overweight and obese subjects leads to a beneficial effect on bone formation and thus, acts as a protector against osteoporosis (6). It has been indicated that obesity enhances bone mass and reduces fracture risk (7). On the contrary, it has also been shown that overweight patients have an increased risk of fracture (5). Different mechanisms play a role in bone metabolism in obese patients. Increased proinflammatory cytokines, alterations in bone turnover, and hormonal and mechanical loading on

bone in obese patients are among these mechanisms (8). Leonard et al. (9) concluded that obesity during childhood and adolescence was associated with increased whole-body bone dimensions and mass. Studies have shown that obesity affects cortical bone rather than trabecular bone (10).

One of the important factors that affect childhood growth is nutrition (11). While excess body weight is related to early pubertal growth, poor nutrition is associated with delayed pubertal growth spurt (12). The effect of childhood obesity on skeletal maturation was previously investigated in the literature and it was shown to be associated with early pubertal development and taller stature (13). Akridge et al. (4) used Fishman's hand-wrist analysis to assess whether increased BMI results in accelerated skeletal age and their results showed that overweight and obese children did not have significantly accelerated skeletal maturation after age and gender adjusting.

Skeletal maturation is an important factor in the planning of an orthodontic treatment which may contain growth modulation to correct skeletal discrepancies of the jaws. Compared to chronological age, skeletal age determination is more secure to determine physical maturation. Different methods have been described to assess maturational status. The cervical vertebrae, the elbow, the foot, the ankle, and the hip are the skeletal parts that can provide information about maturation (14). Nevertheless, the hand-wrist radiographs are the most commonly used ones to determine skeletal maturation by orthodontists in many ways (15). The hand-wrist radiographs are highly correlated with chronological age than other skeletal parts (16). Besides different methods of skeletal age assessment, hand-wrist radiographs could also be used to assess the metacarpal index (MCI).

MCI is a measure of bone mass quantification that stands for the cortical thickness of long bones relative to the outer bone diameter at the measuring site. It could be accepted as a relative evaluation of

the cortical bone thickness. Barnett and Nordin (17) firstly described MCI in 1960 which represents the cortical thickness of the mid-second metacarpal at the radial plus ulnar sides divided by the outer width of the same bone. It is considered as one of the evaluation methods of osteoporosis and fracture risk and digital X-ray radiogrammetry offers the advantage of practical MCI measurement (18). Cortical thickness of the metacarpals and accordingly the MCI decreases with age like in other long bones, especially after menopause in women, and it represents a risk factor for fracture (19,20).

Considering the effect of obesity on bone metabolism, the aim of this study was to investigate metacarpal bone geometry in normal-weight, overweight and obese orthodontic children and adolescents at different pubertal stages.

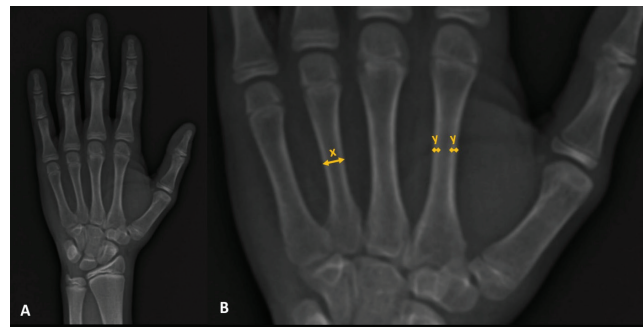
### Materials and Methods

The local research ethics committee of the Ordu University Granted Ethical Approval for the study (no: 2018/23). Patients with general health problems, bone diseases, syndromes, endocrine diseases, metabolic disorders and trauma or surgery history to the hand-wrist were not included. The hand-wrist radiographs of low quality were excluded. This cross-sectional radiographic study was performed in 124 subjects who referred to the Ordu University, Department of Orthodontics. Informed consents were taken from the parents of the subjects that were below the age of 18. According to the BMI percentile, three groups were generated. Normal-weight, overweight and obese groups comprised 48 (18 males, 30 females; mean age,  $13.92 \pm 2.43$  years), 37 (10 males, 27 females; mean age,  $13.98 \pm 2.59$  years) and 39 (16 males, 23 females; mean age,  $12.82 \pm 2.38$  years) subjects, respectively. Distribution of the groups according to BMI, gender and chronologic age were given in Table 1. No statistically significant differences in age and gender were observed between the groups. The sample size was determined by G\*Power Software version 3.1.9.2 (Universität Düsseldorf, Germany) for the second MCI at alpha error probability of 0.05 and a power of 90%. The power analysis showed that 80 samples were required. To strengthen the study, a total of 124 subjects were included in the present study.

With the use of a mechanical weighing scale with 0.1 kg accuracy and a wall-mounted stadiometer with the graduation of 1 mm, the patient's body weight and height were obtained and BMI calculation was carried out by dividing weight (kilogram) to the square of height (meters) at the patient's first visit to the clinic. Age- and gender-specific BMI percentiles were calculated using the Centers for Disease Control and Prevention (CDC) guidelines (21). Patients were classified according to their BMI as follows: 5<sup>th</sup>-84<sup>th</sup> percentiles were characterized as normal-weight, 85<sup>th</sup>-94<sup>th</sup> percentile were characterized as overweight, and above 95<sup>th</sup> percentile were characterized as obese.

All left hand-wrist radiographs were obtained by the same roentgraphic film device (Kodak 8000C Digital Panoramic and Cephalometric System, Cephalostat, Corestream Health Inc, Rochester NY, US). Measurements of the second and fourth metacarpal bones' cortical thickness and width were performed at the midpoint of the bones, using a cephalometric software program (Foxit Reader software, Foxit Corporation, Fremont, CA, USA) by the same investigator after calibration and after that, MCI values were calculated (Figure 1A, B).

To also analyze the effect of pubertal growth stage on the MCI of overweight and obese patients, the



**Figure 1A:** Hand-wrist radiograph; **B:** Measurements of width (X) and cortical thickness (Y) of metacarpal bone

**Table 1. Distribution of the groups according to body mass index percentile, gender and chronologic age**

Groups	Male/female	Age
Normal-weight	18/30	13.92 (2.43)
Overweight	10/27	13.98 (2.59)
Obese	16/23	12.82 (2.38)
p	0.414 <sup>a</sup>	0.066 <sup>b</sup>

<sup>a</sup>: Results of chi-square test, <sup>b</sup>: Results of One-Way ANOVA test

patients were classified according to their growth stage by Fishman skeletal maturation stages on the hand-wrist radiographs (22). However, when the patients were divided into 11 groups using Fishman's method, the groups did not have a sufficient number of patients. Therefore, the patients were divided into 2 growth stages to represent before and after pubertal growth peak periods. Growth stage 1 (GS1) comprised patients that were in stages 1-5 and growth stage 2 (GS2) contained patients with stages of 6-11 according to Fishman's method.

### Statistical Analysis

All statistical analyses were performed by using SPSS (SPSS for Windows version 20.0; SPSS Inc, Chicago, IL) program. After performing the normal distribution test, non-parametric tests were performed to the parameters with non-normal distributions, while parametric tests were applied to the parameters having a normal distribution. Comparison of the groups according to BMI percentile, gender and chronologic age were performed by chi-square and One-way ANOVA tests, respectively. Comparisons between second and fourth metacarpal bone cortical thickness, width and MCI measurements among the different BMI percentile groups were performed using the One-way ANOVA, Kruskal-Wallis and post-hoc tests. In all statistical tests, values of  $p < 0.05$  were considered statistically significant.

### Results

The second metacarpal bone's cortical thickness, width and MCI values were significantly different among normal-weight, overweight and obese patients, while only cortical thickness and width values of the

fourth metacarpal bone were significantly different ( $p < 0.05$ ). No significant difference was observed for the fourth metacarpal bone MCI values. Post-hoc comparisons showed that the significant differences were between normal weight-overweight and normal weight-obese patient groups, with higher values in overweight and obese groups compared to normal-weight group. Overweight-obese groups did not differ from each other significantly for the measured parameters (Table 2).

Table 3 displays the cortical thickness, width and MCI values of second and fourth metacarpal bones of the different BMI percentile groups at different pubertal growth stages. Significant differences were found in second and fourth metacarpal bones' cortical thickness and width between normal-weight, overweight and obese patients before pubertal GS1 ( $p < 0.05$ ). All of the measured parameters of second and fourth metacarpal bones were significantly different among the weight groups after the pubertal peak period (GS2) ( $p < 0.05$ ). Statistically significant differences were found at some of the investigated parameters between normal-weight and obese subjects at GS1, while more parameters differed significantly between normal weight-overweight and normal weight-obese subjects at GS2 using post-hoc tests ( $p < 0.05$ ). Overweight and obese patients have significantly higher values in these parameters, compared to normal-weight patients. No significant differences were observed between overweight-obese groups according to the pubertal growth stage.

### Discussion

Childhood and adolescent overweight and obesity prevalence are rising in almost all industrialized

**Table 2. Metacarpal index, cortical thickness and width of second and fourth metacarpal bones of the different body mass index percentile groups**

	Parameters	Normal-weight	Overweight	Obese	p	Post-hoc test <sup>§</sup>		
						N-OW	N-O	OW-O
2 <sup>nd</sup> Metacarpal bone	Cortical thickness	1.84 (0.32)	2.22 (0.44)	2.13 (0.30)	0.000 <sup>a</sup>	0.000	0.001	0.494
	Width	6.31 (0.66)	6.93 (0.85)	6.99 (0.77)	0.000 <sup>b</sup>	0.001	0.000	0.954
	Metacarpal index	0.58 (0.08)	0.64 (0.09)	0.61 (0.08)	0.022 <sup>b</sup>	0.007	0.153	0.183
4 <sup>th</sup> Metacarpal bone	Cortical thickness	1.45 (0.18)	1.67 (0.31)	1.67 (0.27)	0.000 <sup>a</sup>	0.000	0.000	0.999
	Width	5.33 (0.49)	5.75 (0.67)	5.69 (0.70)	0.003 <sup>a</sup>	0.006	0.019	0.919
	Metacarpal index	0.55 (0.06)	0.58 (0.09)	0.59 (0.10)	0.107 <sup>b</sup>	0.181	0.038	0.571

p<sup>a</sup>: Results of One-way ANOVA test, p<sup>b</sup>: Results of Kruskal-Wallis test, §: Post-hoc Tukey's honestly significant difference test for parametric data and Mann-Whitney U test for non-parametric data, N: Normal-weight, OW: Overweight, O: Obese groups



countries. Childhood obesity has been associated with multiple general health problems such as endocrine diseases, metabolic and cardiovascular issues (12,23), obstructive sleep apnea, gastrointestinal diseases, orthopedic complications (24), low self-esteem (25), musculoskeletal complaints (26) and fractures (27).

Controversial results were found in the studies analyzing the effect of obesity on bone metabolism. Several studies demonstrated that overweight and obese children have a significantly higher bone mineral density (BMD) and bone mineral content (BMC) (28-30). Enhanced adipose tissue in childhood obesity is considered as the ground for enhanced total BMD through increased mechanical load on the bone (9,30). Leonard et al. (9) investigated the effect of childhood obesity on skeletal mass and dimensions in 132 non-obese and 103 obese subjects and their findings suggested that obesity in children and adolescents resulted in enhanced vertebral bone density and enhanced whole-body bone dimensions and mass. In their review that was conducted on twenty-seven studies and a total of 5958 children, van Leeuwen et al. (31) showed that overweight and obese children had a higher peak bone mass, BMD and BMC than normal-weight children. They also indicated that being obese compared with overweight

does not have as much difference as being obese or overweight compared with being of normal weight in terms of BMD and BMC. In contrast with the studies that identify a positive relationship between obesity and bone mass, there are also a few studies in the literature showing a negative relationship between these two (10,32).

In accordance with the findings of the studies showing a positive association between obesity and bone mass and dimensions, our results showed an enhanced metacarpal width and cortical thickness in overweight and obese adolescents than normal-weight patients and no statistically significant difference was observed between overweight and obese subjects.

Oestrogen is a substantial factor in bone metabolism. Oestrogen deficiency results in an increased osteoclast formation and an imbalance in bone remodeling and accordingly, bone mass reduction (33). Fat tissue plays an important role in oestrogen metabolism. Therefore, overweight and obese patients have enhanced oestrogen levels that cause a favorable effect on bone formation (34). Other than oestrogen, leptin is also a significant determinative in bone metabolism. With its effect on regulating appetite, leptin is a mediator that is

**Table 3. Metacarpal index, cortical thickness and width of second and fourth metacarpal bones of the different body mass index percentile groups according to pubertal growth stage**

Growth stage	Metacarpal bone	Parameters	Normal-weight	Overweight	Obese	p	Post-hoc test <sup>§</sup>		
							N-OW	N-O	OW-O
GS1	2 <sup>nd</sup> Metacarpal bone	Cortical thickness	1.52 (0.17)	1.74 (0.42)	1.91 (0.16)	0.002 <sup>a</sup>	0.153	0.001	0.332
		Width	5.90 (0.21)	6.33 (0.99)	6.84 (0.34)	0.001 <sup>b</sup>	0.843	0.000	0.128
		Metacarpal index	0.52 (0.06)	0.54 (0.05)	0.56 (0.04)	0.135 <sup>a</sup>	0.459	0.123	0.863
	4 <sup>th</sup> Metacarpal bone	Cortical thickness	1.34 (0.16)	1.45 (0.29)	1.56 (0.20)	0.044 <sup>a</sup>	0.472	0.034	0.548
		Width	5.32 (0.45)	5.78 (0.78)	5.80 (0.33)	0.048 <sup>b</sup>	0.219	0.022	0.176
		Metacarpal index	0.51 (0.07)	0.50 (0.04)	0.54 (0.06)	0.321 <sup>a</sup>	0.984	0.394	0.415
GS2	2 <sup>nd</sup> Metacarpal bone	Cortical thickness	1.96 (0.28)	2.33 (0.36)	2.23 (0.29)	0.000 <sup>a</sup>	0.000	0.004	0.431
		Width	6.47 (0.70)	7.07 (0.76)	7.06 (0.89)	0.003 <sup>a</sup>	0.007	0.011	0.999
		Metacarpal index	0.61 (0.07)	0.66 (0.08)	0.64 (0.08)	0.027 <sup>a</sup>	0.020	0.365	0.426
	4 <sup>th</sup> Metacarpal bone	Cortical thickness	1.49 (0.18)	1.72 (0.29)	1.72 (0.28)	0.000 <sup>a</sup>	0.001	0.002	0.999
		Width	5.33 (0.51)	5.74 (0.66)	5.64 (0.81)	0.034 <sup>a</sup>	0.036	0.151	0.846
		Metacarpal index	0.56 (0.05)	0.60 (0.09)	0.62 (0.10)	0.021 <sup>a</sup>	0.115	0.023	0.760

p<sup>a</sup>: Results of One-way ANOVA test, p<sup>b</sup>: Results of Kruskal-Wallis test, §: Post-hoc Tukey's honestly significant difference test for parametric data and Mann-Whitney U test for non-parametric data, GS1: Before pubertal growth pick period, GS2: After pubertal growth pick period; N: Normal-weight, OW: Overweight, O: Obese groups.

secreted by adipocytes. It plays a critical role in skeletal development (35). Obese patients have increased proinflammatory leptin levels (36). As the amount of fat in the body increases, the leptin concentration also increases. Acting as a growth factor on skeletal growth centers' chondrocytes, increased leptin levels in obese and overweight children result in enhanced bone mass than normal-weight children (37,38). Potentially increased leptin and oestrogen levels in overweight and obese subjects in this study may have an effect on increased metacarpal bone cortical thickness and width.

The revised CDC BMI percentile charts which are considered as a standard for children and adolescents aged between 2 and 20 were used in the present study. Clinical use of BMI percentile is the most rapid and practical method to assess weight status. However, the separation between fat tissue and muscle is not possible when defining a subject as overweight or obese using the BMI percentile and it should not be taken into account as a definitive marker of overweight and obesity. Subjects considered as obese using BMI percentile might not have excess adipose tissue. Diagnosis of overweight and obesity could be supported with other methods of adiposity analysis such as dual energy X-ray absorptiometry, skin-fold thickness, air-displacement plethysmography, hydrostatic weighing, arm and waist circumferences, isotope dilution, bioelectrical impedance analysis, computerized tomography and magnetic resonance imaging (39,40).

The effect of fat mass on bone growth is shown to be related to the stage of puberty (41). The strength of this study is that the effect of growth stages and pubertal growth peak was also taken into consideration while assessing the effect of obesity on metacarpal bone geometry. The lack of prospective data to analyze the long-term effect of obesity on metacarpal cortical thickness, width and MCI can be considered a limitation of this study due to its cross-sectional design. Further long-term prospective researches should be designed.

### Conclusion

Overweight and obese adolescents have significantly greater metacarpal bone parameters than normal-weight patients. Orthodontists should be aware of these metacarpal bone changes whilst

evaluating hand-wrist radiographs for treatment timing and planning in overweight and obese patients.

### Ethics

**Ethics Committee Approval:** The local research ethics committee of the Ordu University granted ethical approval for the study (decision no: 2018/23, date: 01/02/2018).

**Informed Consent:** Informed consents were taken from the parents of the subjects that were below the age of 18.

**Peer-review:** Externally peer-reviewed.

### Authorship Contributions

Concept: S.K.B., Y.N.K., Design: H.Ş., Data Collection or Processing: S.K.B., Analysis or Interpretation: Y.N.K., S.K.B., Literature Search: Y.N.K., Writing: Y.N.K., S.K.B.

**Conflict of Interest:** No conflict of interest was declared by the authors.

**Financial Disclosure:** The authors declared that this study received no financial support.

### References

1. Guo SS, Huang C, Maynard LM, Demerath E, Towne B, Chumlea WC, et al. Body mass index during childhood, adolescence and young adulthood in relation to adult overweight and adiposity: the Fels Longitudinal Study. *Int J Obes Relat Metab Disord* 2000; 24: 1628.
2. Kopelman PG. Obesity as a medical problem. *Nature* 2000; 404: 635.
3. Haroun D, Wells JC, Williams JE, Fuller NJ, Fewtrell MS, Lawson MS. Composition of the fat-free mass in obese and nonobese children: matched case-control analyses. *Int J Obes* 2005; 29: 29-36.
4. Akridge M, Hilgers KK, Silveira AM, Scarfe W, Scheetz JP, Kinane DF. Childhood obesity and skeletal maturation assessed with Fishman's hand-wrist analysis. *Am J Orthod Dentofacial Orthop* 2007; 132: 185-90.
5. Maiano C. Prevalence and risk factors of overweight and obesity among children and adolescents with intellectual disabilities. *Obes Rev* 2011; 12: 189-97.
6. Villareal DT, Apovian CM, Kushner RF, Klein S. Obesity in older adults: technical review and position statement of the American Society for Nutrition and NAASO, The Obesity Society. *Obes Res* 2005; 13: 1849-63.
7. De Laet C, Kanis J, Odén A, Johanson H, Johnell O, Delmas P, et al. Body mass index as a predictor of fracture risk: a meta-analysis. *Osteoporos Int* 2005; 16: 1330-8.
8. Shapses SA, Sukumar D. Bone metabolism in obesity and weight loss. *Annu Rev Nutr* 2012; 32: 287-309.
9. Leonard MB, Shults J, Wilson BA, Tershakovec AM, Zemel BS. Obesity during childhood and adolescence augments bone mass and bone dimensions. *Am J Clin Nutr* 2004; 80: 514-23.

10. Longhi S, Pasquino B, Calcagno A, Bertelli E, Olivieri I, Di Iorgi N et al. Small metacarpal bones of low quality in obese children. *Clin Endocrinol* 2013; 78: 79-85.
11. Gat-Yablonski G, Yackobovitch-Gavan M, Phillip M. Nutrition and bone growth in pediatrics. *Pediatr Clin North Am* 2011; 58: 1117-40.
12. Solorzano CMB, McCartney CR. Obesity and the pubertal transition in girls and boys. *Reproduction* 2010; 140: 399-410.
13. Kaplowitz PB. Link between body fat and the timing of puberty. *Pediatrics* 2008; 121: 208-17.
14. Hassel B, Farman AG. Skeletal maturation evaluation using cervical vertebrae. *Am J Orthod Dentofacial Orthop* 1995; 107: 58-66.
15. Moore RN, Moyer BA, DuBois LM. Skeletal maturation and craniofacial growth. *Am J Orthod Dentofacial Orthop* 1990; 98: 33-40.
16. Zerlin JM, Hernandez RJ. Approach to skeletal maturation. *Hand Clin* 1991; 7: 53-62.
17. Barnett E, Nordin BE. The radiological diagnosis of osteoporosis: a new approach. *Clin Radiol* 1960; 11: 166-74.
18. Hyldstrup L, Nielsen SP. Metacarpal index by digital X-ray radiogrammetry: normative reference values and comparison with dual X-ray absorptiometry. *J Clin Densitom* 2001; 4: 299-306.
19. Nielsen SP. The metacarpal index revisited: a brief overview. *J Clin Densitom* 2001; 4: 199-207.
20. Adami S, Zamberlan N, Gatti D, Zanfisi C, Braga V, Brogginini M, et al. Computed radiographic absorptiometry and morphometry in the assessment of postmenopausal bone loss. *Osteoporos Int* 1996; 6: 8-13.
21. Kuczmarski RJ, Ogden CL, Grummer-Strawn LM, Flegal KM, Guo SS, Wei R, et al. CDC growth charts; United States. *Adv Data* 2000; 314: 1-27.
22. Fishman LS. Radiographic evaluation of skeletal maturation: a clinically oriented method based on hand-wrist films. *Angle Orthod* 1982; 52: 88-112.
23. Han JC, Lawlor DA, Kimm SY. Childhood obesity. *Lancet* 2010; 375: 1737-48.
24. Slyper AH. Childhood obesity, adipose tissue distribution, and the pediatric practitioner. *Pediatrics* 1998; 102: e4.
25. Strauss RS. Childhood obesity and self-esteem. *Pediatrics* 2000; 105: e15.
26. Paulis W, Silva S, Koes B, Middelkoop M. Overweight and obesity are associated with musculoskeletal complaints as early as childhood: a systematic review. *Obes Rev* 2014; 15: 52-67.
27. Adams AL, Kessler JI, Deramerian K, Smith N, Black MH, Porter AH, et al. Associations between childhood obesity and upper and lower extremity injuries. *Inj Prev* 2013; 19: 191-7.
28. Doyle F, Brown J, Lachance C. Relation between bone mass and muscle weight. *Lancet* 1970; 1: 391-3.
29. Nava-González EJ, Cerda-Flores RM, García-Hernández PA, Jasso-de la Peña GA, Bastarrachea RA, Gallegos-Cabriales EC. Densidad mineral ósea y su asociación con la composición corporal y biomarcadores metabólicos del eje insulino-glucosa, hueso y tejido adiposo en mujeres. *Gac Med Mex* 2015; 151: 731-40.
30. Kemp JP, Sayers A, Smith GD, Tobias JH, Evans DM. Using Mendelian randomization to investigate a possible causal relationship between adiposity and increased bone mineral density at different skeletal sites in children. *Int J Epidemiol* 2016; 45: 1560-72.
31. van Leeuwen J, Koes BW, Paulis WD, van Middelkoop M. Differences in bone mineral density between normal-weight children and children with overweight and obesity: a systematic review and meta-analysis. *Obes Rev* 2017; 18: 526-46.
32. Goulding A, Taylor RW, Jones IE, McAuley KA, Manning PJ, Williams SM. Overweight and obese children have low bone mass and area for their weight. *Int J Obes Relat Metab Disord* 2000; 24: 627.
33. Johnson R, Gilbert J, Cooper R, Parsell D, Stewart B, Dai X, et al. Effect of estrogen deficiency on skeletal and alveolar bone density in sheep. *J Periodontol* 2002; 73: 383-91.
34. Kershaw EE, Flier JS. Adipose tissue as an endocrine organ. *J Clin Endocrinol Metab* 2004; 89: 2548-56.
35. Takeda S, Karsenty G. Central control of bone formation. *J Bone Miner Metab* 2001; 19: 195-8.
36. Kelley JC, Crabtree N, Zemel BS. Bone Density in the Obese Child: Clinical Considerations and Diagnostic Challenges. *Calcif Tissue Int* 2017; 100: 514-27.
37. Maor G, Rochwerger M, Segev Y, Phillip M. Leptin acts as a growth factor on the chondrocytes of skeletal growth centers. *J Bone Miner Res* 2002; 17: 1034-43.
38. Dimitri P, Jacques RM, Paggiosi M, King D, Walsh J, Taylor ZA, et al. Leptin may play a role in bone microstructural alterations in obese children. *J Clin Endocrinol Metab* 2015; 100: 594-602.
39. Kim CH. Measurements of adiposity and body composition. *Korean J Obes* 2016; 25: 115-20.
40. Styne DM, Arslanian SA, Connor EL, Farooqi IS, Murad MH, Silverstein JH, et al. Pediatric obesity—assessment, treatment, and prevention: an Endocrine Society Clinical Practice guideline. *J Clin Endocrinol Metab* 2017; 102: 709-57.
41. Dimitri P, Wales JK, Bishop N. Fat and bone in children: differential effects of obesity on bone size and mass according to fracture history. *J Bone Miner Res* 2010; 25: 527-36.