

# Comparison of Facial Soft Tissue Features of Older Adults by Gender: A Pilot Study

## Yaşlı Erişkin Dönemdeki Bireylerin Yüz Yumuşak Doku Özelliklerinin Cinsiyetlere Göre Karşılaştırılması: Pilot Çalışma

✉ Ender Akan<sup>1</sup>, ✉ Burçin Akan<sup>2</sup>

<sup>1</sup>İzmir Katip Celebi University Faculty of Dentistry, Department of Prosthodontics, İzmir, Turkey

<sup>2</sup>İzmir Katip Celebi University Faculty of Dentistry, Department of Orthodontics, İzmir, Turkey



### Abstract

**Objective:** The purpose of this study is to investigate the facial soft tissues dimensions of the individuals 50–60 ages and compare between sexes by using images obtained from 3D facial scanning system.

**Materials and Methods:** Twenty six individuals (13 males; 55.54±2.99 years, 13 females; 54.46±3.31 years) with no loss of occlusal vertical dimensions and anterior teeth in department of prosthodontics were included in the study. Linear and angular measurements of anatomical marks on 3dMD images were made. Statistical analyse (Independent samples t-test) was performed to compare the differences.

**Results:** There were statistically significant differences in lip length, lower face height, nose width, lower face width, lower lip and nasomental angle were found between sexes.

**Conclusion:** Facial soft tissue widths and heights were less in female than male.

### Keywords

Facial soft tissue, 3dMD, older adults, gender

### Anahtar Kelimeler

Yüz yumuşak dokusu, 3dMD, yaşlı erişkin, cinsiyet

Received/Geliş Tarihi : 03.09.2021

Accepted/Kabul Tarihi : 30.03.2022

doi:10.4274/meandros.galenos.2022.03789

### Address for Correspondence/Yazışma Adresi:

Ender Akan Assoc. Prof. MD,  
İzmir Katip Celebi University Faculty of  
Dentistry, Department of Prosthodontics,  
İzmir, Turkey  
Phone : +90 555 714 37 70  
E-mail : enderakan@gmail.com  
ORCID ID: orcid.org/0000-0002-4596-2612

### Öz

**Amaç:** Bu çalışmanın amacı, 3B yüz tarama sisteminden elde edilen görüntüleri kullanarak 50–60 yaş arası bireylerin yüz yumuşak doku boyutlarını değerlendirmek ve cinsiyetler arası karşılaştırma yapmaktır.

**Gereç ve Yöntemler:** Çalışmaya protetik diş tedavisi anabilim dalında oklüzal dikey boyut ve ön diş kaybı olmayan 26 kişi (13 erkek; 55,54±2,99 yıl, 13 kadın; 54,46±3,31 yıl) dahil edildi. 3dMD görüntüleri üzerinde lineer ve açısal ölçümler yapıldı. Gruplar arası değerleri karşılaştırmak için bağımsız örneklem t testi kullanıldı.

**Bulgular:** Veriler dudak uzunluğu, alt yüz yüksekliği, burun genişliği, alt yüz genişliği, alt dudak ve burun açısında cinsiyetler arasında istatistiksel olarak anlamlı değişiklikler olduğunu ortaya koydu.

**Sonuç:** Kadınlarda fasiyal yumuşak doku genişlikleri ve yükseklikleri erkeklere göre daha azdır.

## Introduction

The structure and the proportions of the soft tissues provide visual effects of the face. Aging significantly changes the appearance of the human face. According to Albert et al. (1) and Rhodes (2) facial ageing is essentially due to skin-related deformations caused by bone movement, bone growth, the appearance of wrinkles and decreased muscle strength. While bone growth usually occurs during childhood, age-related deformations in adulthood are mostly associated with tissue changes.

There are many studies reporting that there are differences between the sexes as well as the age-related variations in the dimension of the facial soft tissues (3-5). Ozdemir et al. (3) researched to detect facial soft tissue values of young adults in Turkey. They reported that cranial, facial, nasal, and orolabial parameters, have significant gender-related differences. The most significant differences between the genders were observed in the data gained from the face.

Extraoral photographs, which have become our routine in the clinical evaluation of facial soft tissues, are insufficient to obtain a one-to-one three-dimensional (3D) image and they are difficult to analyze. With stereophotogrammetry, which is a method that is easy to obtain and allows working on all 3 planes, 3D data can be obtained by combining images from different angles from the same plane (6). Stereophotogrammetry is a very popular method, especially in orthodontics, plastic reconstructive surgery and maxillofacial surgery, as it allows specific soft tissue evaluation (7). This method, besides enabling 3D study, will appear both as a routine recording method and as an auxiliary diagnostic method in the prosthetic planning phase.

According to the age distribution of Turkey's population in 2020, individuals between the ages of 50-60 constitute approximately 11% of the total population (8). It has been determined that 48% of those who applied to our institution for prosthetic treatments between 2013-2021 were between the ages of 50-60. Considering that prosthetic treatment may cause soft tissue changes, it is necessary to examine the norms of facial soft tissue features of this age group has arisen.

Although the studies in the literature give a detailed information about the changes that occur with the growth of the soft tissue profile, there are limited studies examining the changes that occur in the facial soft tissues with aging. In addition, it was seen that mostly soft tissue thicknesses were examined in studies, and linear or angular parameters were not evaluated (9,10).

The aim of this retrospective research is to examine the facial soft tissue dimensions and differences between genders of individuals between the ages of 50-60.

## Materials and methods

This study was carried out with ethical approval from Izmir Katip Celebi University Ethics Committee (protocol number: 2021-GOKAE-0414, date: 26/08/2021).

The effect size was calculated according to the nasofacial angle between the groups in the study of Baik et al. (11) using the G\* Power software (version 3.1.9.2; Heinrich Heine University, Düsseldorf, Germany), and found to be 1.13. Accordingly, the required number of subjects providing at least 85% power at  $\alpha=0.05$  significance level was calculated as 12 per group (critical  $t=2.777$ ; noncentrality parameter  $=1.1717$ ). According to the inclusion criteria, 13 patients were included in this study.

The selection criteria were: 1- being between the ages of 50 and 60, 2- no loss of opposing molars (no loss of occlusal vertical dimensions), 3- no lack of anterior teeth, 4- no significant transversal, sagittal and vertical skeletal malocclusion, 5- normal body mass index (BMI), 6- not having diseases affecting the soft tissue, muscle and nervous system that define paralysis, 7- not having obvious asymmetry in facial soft tissues and 8- no history of facial trauma.

BMI was calculated according to the "National Center for Chronic Disease Prevention and Health Promotion". For adults 20 years old and older, BMI is interpreted using standard weight status categories which are the same for men and women of all body types and ages. Accordingly, after calculating the BMI [weight (kg)/height (m<sup>2</sup>)] for all patients, individuals between 18.5-24.9 were included in our study.

While taking 3D facial scan image recordings from the patient, care was taken to ensure that the patient was in centric occlusion, the teeth were in maximum

intercuspidation, the muscles were not tension-free, and the lips were in slight contact. In order to achieve this position, the patients were asked to close their jaws in the position where their teeth were best clenched and to remain in a relaxed position without tension (12), and records were taken using the 3dMDface™ (3dMD Inc., Atlanta, GA, USA) system while in this position.

The 3dMDvultus analysis program (3dMD Inc., Atlanta, Ga, USA) was used to analyze the 3D data obtained with the 3dMD imaging system. Before determining the points on the 3-dimensional images in the program, it was ensured that the images were placed in appropriate and standard positions in the 3-dimensional space (12). The reference points are marked after the reference planes have been created on the 3D facial image (Figure 1).

Landmarks and measurements were presented in Tables 1 and 2. All measurements were conducted by a single researcher (B.A.). To determine the method error, the same author repeated the measurements 1 week after the first measurements on 10 3D images randomly selected.

### Statistical Analysis

All statistical analyses were performed using IBM SPSS Statistics 22.0 (IBM Corp., Armonk, New York, USA). The normal distribution of the numerical variables was evaluated by the Shapiro-Wilk test and none of the variables violated the normality assumption. Thus, statistical evaluation was performed using the parametric test. A student t-test was used for comparison of groups. The statistical significance level was 0.05 in all statistical analyses.

### Results

According to the results of an intraclass correlation analysis to determine methodological errors, correlation coefficients were found ranging from 0.9 to 1.00. The minimum and maximum coefficients were between 0.961 and 0.996.

Mean age of patients were  $54.46 \pm 3.31$  years in female group and  $55.54 \pm 2.99$  years in male group. There was no significant difference between age ( $p=0.392$ ).

Soft tissue values of adults in similar age groups by sexes are shown in Table 3. Upper lip length, lower

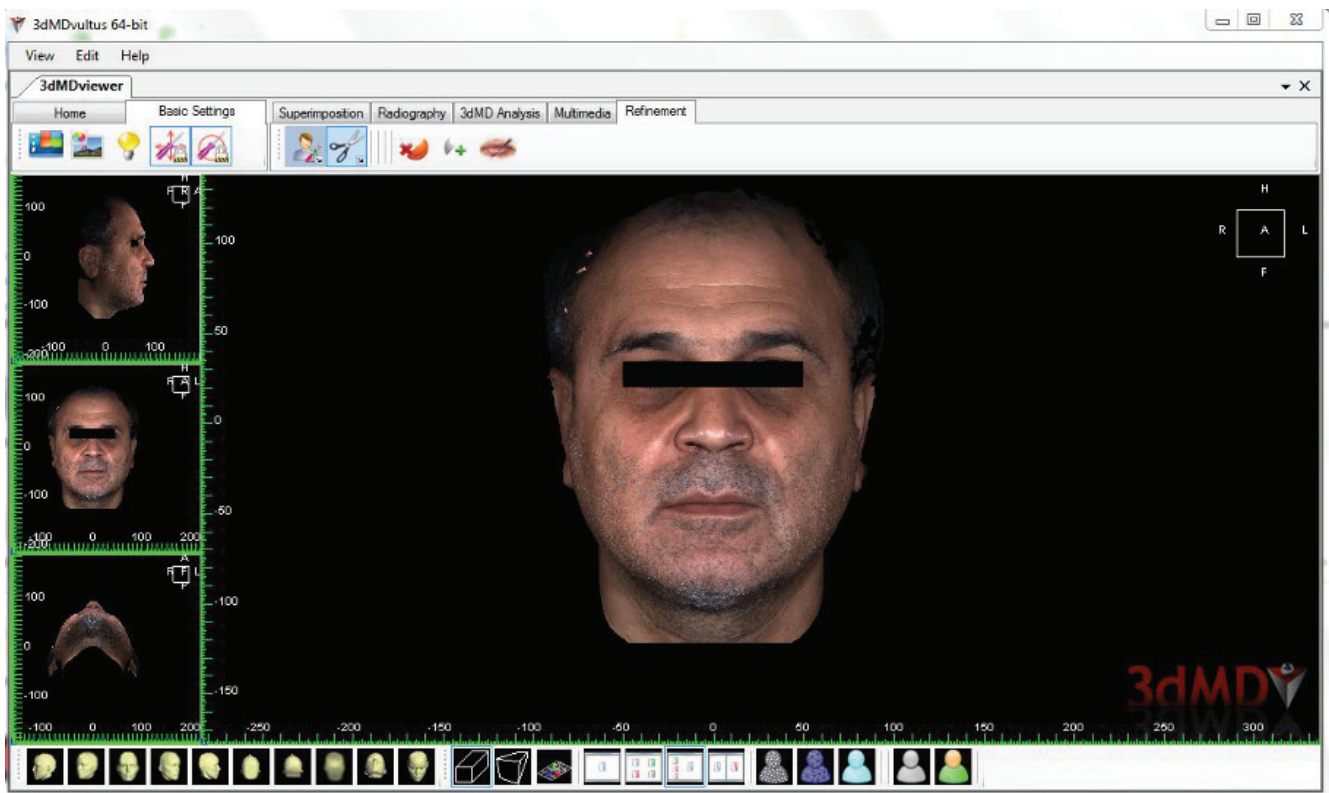


Figure 1. 3D facial image

<b>Table 1. Soft tissue landmarks used in the study</b>	
<b>Soft Tissue Point (Abbreviation)</b>	<b>Description</b>
Glabella (gl)	The most anterior and midpoint of the fronto-orbital soft tissue contour
Tragion (tr-tl)	Soft tissue point of the superior margin of the tragus
Nasion (n)	The deepest point of the nasal bridge
Pronasale (prn)	Tip of the nose
Subnasale (sn)	Midpoint of the angle at the base of the columella
Alare (alr-all)	The most outer point of the nose wing
Crista philtra (cphr-chpl)	The highest right and left points of the vermilion line
Chelion (chr-chl)	Lip corner point
Labiale superius (ls)	Midpoint of the upper vermilion line
Labiale inferius (li)	Midpoint of the lower vermilion line
Stomion (sto)	Midpoint of the labial fissure when the lips are closed naturally
B point (b)	The deepest point of the labiomental soft tissue contour
Gonion (gor-gol)	The most lateral point at the angle of the mandible
Pogonion(pog)	The most protruding middle point on the front surface of the chin
Menton (me)	The lowest point of the soft tissue contour of the chin tip

<b>Table 2. Definition of measurements for 3dMD image</b>	
<b>Linear measurements</b>	
Nasal width (alr-all)	Transverse lineer measurement from alara right to left
Philtrum width (cphr-cphl)	Transverse lineer measurement from christa philtra right to left
Mouth width (chr-chl)	Transverse lineer measurement from chelion right to left
Upper lip length (sto-sn)	Vertical lineer measurement from stomion to subnasale
Upper lip vermilion length (sto-ls)	Vertical lineer measurement from stomion to labiale superius
Lower lip length (sto-me)	Vertical lineer measurement from stomion to soft tissue menton
Lower lip vermilion length (sto-li)	Vertical lineer measurement from stomion to labiale inferius
Anterior face height (n-me)	Vertical lineer measurement from soft tissue nasion to soft tissue menton
Lower face height (sn-gn)	Vertical lineer measurement from subnasale to soft tissue gnathion
Mid-face width (tr-tl)	Transverse lineer measurement from tragion right to left
Lower face width (gor-gol)	Transverse lineer measurement from soft tissue gonion right to left
<b>Angular measurements</b>	
Nasofrontal angle (g-n-prn)	Angular measurement from soft tissue glabella to nasion to pronasale
Nasolabial angle (s-sn-ls)	Angular measurement from soft tissue columella to subnasale to labiale superius
Labiomental angle (li-b-pog)	Angular measurement from labiale inferius to soft tissue b to pogonion
Convexity angle (n-sn-pog)	Angular measurement from soft tissue nasion to subnasale and soft tissue pogonion
Nasomental angle (n-prn-pog)	Angular measurement from soft tissue nasion to pronasale to soft tissue pogonion
Upper lip angle (chr-ls-chl)	Angular measurement from right cheilion to labiale superius to left cheilion
Lower lip angle (chr-li-chl)	Angular measurement from right cheilion to labiale inferius to left cheilion
Interlabial angle (ls-sto-li)	Angular measurement from labiale superius to stomion to labiale inferius
Facial angle (g-sn-pog)	Angular measurement from soft tissue glabella to subnasale to soft tissue pogonion
Nasofacial angle (prn-sn-pog)	Angular measurement from pronasale to subnasale to soft tissue pogonion

face height, nose width, lower face width and lower lip angle were found to be less in female compared to male ( $p < 0.05$ ). The nasomental angle was found to be higher in female ( $p = 0.036$ ).

**Table 3. Comparison of measurements on the facial soft tissue between sexes**

	Female		Male		p
	Mean	SD	Mean	SD	
<b>Linear measurements</b>					
Alr-all	38.47	4.98	42.71	3.29	0.017
Cphr-cphl	12.58	2.00	13.72	2.70	0.232
Chr-chl	51.63	4.55	54.54	3.16	0.070
Sn-sto	20.82	1.69	24.26	2.54	0.001
Sto-ls	5.44	1.37	6.04	2.20	0.407
Sto-me	45.42	4.07	48.91	6.13	0.100
Sto-li	7.39	1.97	5.65	1.67	0.024
N-me	115.20	8.93	121.46	7.64	0.067
Sn-gn	66.07	5.03	72.67	6.79	0.010
Tr-tl	129.03	8.79	122.53	7.27	0.546
Gor-gol	150.04	6.79	155.89	4.38	0.015
<b>Angular measurements</b>					
G-n-prn	151.17	7.06	157.59	9.14	0.056
C-sn-ls	102.45	7.64	101.54	9.06	0.784
Li-b-pog	136.12	10.28	143.81	10.51	0.237
N-sn-pog	172.46	4.49	168.64	7.21	0.118
N-prn-pog	148.52	3.56	144.58	5.33	0.036
Chr-ls-chl	112.76	6.65	117.31	8.62	0.145
Chr-li-chl	117.51	5.61	124.87	10.22	0.032
Ls-sto-li	119.58	12.99	117.55	13.59	0.826
G-sn-pog	132.16	4.72	129.37	3.78	0.109
Prn-sn-pog	121.25	5.67	124.06	7.32	0.284

**Discussion**

In adults age, numerous changes occur simultaneously within the craniofacial complex. There is a decrease in bone mass especially after the age of 30. Also there are decrease in facial skin elasticity, sagging of the skin, loss of volume in fat tissues, drooping and sagging of fat tissues, and thinning due to resorption in the skull and facial bones can develop (13). Changes in thin and compact bone surfaces can slightly alter the general shape of the human face, especially in the dentoalveolar region. There are many

studies on facial soft tissue norms in the literature (14-16), but it has been observed that the age range of the populations is less. For this purpose, this age group was examined.

Age-related changes in the face affect the accuracy and effectiveness of biometric techniques related to automatic face recognition. Many researchers around the world are working on a wide variety of aspects related to facial aging, synthetic facial aging and facial expression in order to develop computer automatic facial recognition systems. These studies attempt to provide an overview of the intrinsic and extrinsic factors affecting the aging of craniofacial structures and to summarize the effects of facial soft tissue thickness that changes with age and their impact on the general appearance of the face (17). Wilkinson (18) reported that age-related tissue changes are very variable with which decrease in the tissues of the mouth and lower part of the cheek and an increase in the tissues in the chin and eyebrows. In our study, we aimed to create angular and linear norms of facial soft tissues for individuals in the age group we identified.

There are several studies on the dominant role of BMI in the alterations of the facial soft tissue (9,19,20). It has been shown in the literature that body mass is a relevant influential factor in the thickness of the soft tissues of the face and, therefore, should be considered in sex comparisons (9). Therefore, individuals with normal BMI were included in our study.

Ferrario et al. (21) reported that the greatest increase was observed in the vertical dimension in their study, in which they evaluated the normal growth, development and aging of facial soft tissues with 3D computerized mesh diagram analysis, and that the vertical dimension increased even after the age of 30 in male. They also observed that male sizes were larger than female sizes in all age classes (21). Although there is no similar age group, we found that the vertical dimensions in men were higher than women in our study. This can be explained by the fact that the vertical dimensions of males increase more during growth and development.

Velemínská et al. (4) reported that the changes that occur with aging are enlargement of the neurocranium and retraction of the face, including the forehead, especially after the age of 60. They stated that there are similar features between Czech and French samples where she evaluated sexual dimorphism.

Cheung et al. (22) evaluated the 3D images of Chinese adults with an ideal face and occlusion in their study and reported that the lower face height was higher in men than in women.

Packiriswamy et al. (23) reported facial height and width values were significant differences between sexes in nationality subjects aged 18-28 years of Chinese, Indian, and Malay. In all groups, physiognomical facial height was found to be greater in males than in females. In accordance with the literature, anterior and lower face height measurements, in which we evaluated the vertical soft tissue dimensions, were found to be higher in men and a statistical difference was found in the lower face height.

In their study to determine the normal measurement range of the craniofacial complex in some ethnic/racial groups, Farkas et al. (24) measured anterior face height, lower face height, gonial distance, alar distance and chelion distance, similar to the measurements in our study. According to the data obtained, these values were found to be higher in males than females. Bravo-Hammett et al. (25) analyzed 3D imaging to describe the facial morphology of a Colombian population and found that the mean values of Colombian males showed greater measurements than females in the majority of measurements. Similarly, Ozdemir et al. (3) reported that measurements of the face showed that males had wider and higher faces. Baik et al. (11) stated that anterior face height, middle and lower face width, philtrum width, mouth width of male show a statistically significant large than female. In our study, anterior face height, lower face height, gonial distance, alar distance and chelion distance were found to be higher in males, which is consistent with this study. The results of these studies conducted with different age groups make us think that the vertical and width dimensions of men in facial soft tissue dimensions will be higher in all age groups, despite the changes that occur with aging. This situation reveals that it is a factor that should be considered in prosthetic applications that require replanning of the entire occlusion.

In addition to the prosthetic needs of individuals in advanced ages, the gradual increase in their aesthetic expectations has caused the changing soft tissue properties to be taken into account in prosthesis

planning. For example, the appearance of the incisors is a young feature. Incisor display at rest and smile, gingival display on smile, and lip separation at rest all decrease after adolescence in both males and females, particularly beyond 20 years of age (4). Planning the position of the maxillary incisors by considering the changes in soft tissues with age and especially the difference in upper lip length between the sexes in prosthesis planning will affect the aesthetics of the treatment, both short-term and long-term effects.

Our study consisted of a limited number of samples in a certain age range. In order for the study to be applicable to the general population, wider age ranges should be evaluated with a larger sample size.

## Conclusion

Upper lip length was taller in male than in female. Lower face height and width were found to be less in female compared to male.

## Ethics

**Ethics Committee Approval:** This study was carried out with ethical approval from İzmir Katip Celebi University Ethics Committee (protocol number: 2021-GOKAE-0414, date: 26/08/2021).

**Informed Consent:** Retrospective study.

**Peer-review:** Externally and internally peer-reviewed.

## Authorship Contributions

Concept: E.A., Design: E.A., B.A., Data Collection or Processing: E.A., Analysis or Interpretation: B.A., Literature Search: E.A., B.A., Writing: E.A., B.A.

**Conflict of Interest:** No conflict of interest was declared by the authors.

**Financial Disclosure:** The authors declared that this study received no financial support.

## References

1. Albert AM, Ricane K, Patterson E. A review of the literature on the aging adult skull and face: implications for forensic science research and applications. *Forensic Sci Int* 2007; 172: 1-9.
2. Rhodes MG. Age estimation of faces: a review. *Applied Cognitive Psychology* 2009; 23: 1-12.
3. Ozdemir ST, Sigirli D, Ercan I, Cankur NS. Photographic facial soft tissue analysis of healthy Turkish young adults: anthropometric measurements. *Aesthetic Plast Surg* 2009; 33: 175-84.
4. Velemínská J, Fleischmannová N, Suchá B, Dupej J, Bejdová Š, Kotěrová A, et al. Age-related differences in cranial sexual dimorphism in contemporary Europe. *Int J Legal Med* 2021; 135: 2033-44.

5. Dickens ST, Sarver DM, Proffit WR. Changes in frontal soft tissue dimensions of the lower face by age and gender. *World Journal of Orthodontics* 2002; 3: 313-20.
6. Maal TJJ, van Loon B, Plooi JM, Rangel F, Ettema AM, Borstlap WA, et al. Registration of 3-dimensional facial photographs for clinical use. *J Oral Maxillofac Surg* 2010; 68: 2391-401.
7. Topsakal KG. 3-Dimensional imaging systems in orthodontics: Review of literature. *Selcuk Dent J* 2018; 5: 186-93.
8. Available from: <https://data.tuik.gov.tr/Bulten/Index?p=Istatistiklerle-Yaslilar-2020-37227>
9. De Greef S, Vandermeulen D, Claes P, Suetens P, Willems G. The influence of sex, age and body mass index on facial soft tissue depths. *Forensic Sci Med Pathol* 2009; 5: 60-5.
10. Stephan CN, Simpson EK. Facial soft tissue depths in craniofacial identification (part I): an analytical review of the published adult data. *J Forensic Sci* 2008; 53: 1257-72.
11. Baik HS, Jeon JM, Lee HJ. Facial soft-tissue analysis of Korean adults with normal occlusion using a 3-dimensional laser scanner. *Am J Orthod Dentofacial Orthop* 2007; 131: 759-66.
12. Plooi JM, Swennen GR, Rangel FA, Maal TJ, Schutyser FA, Bronkhorst EM, et al. Evaluation of reproducibility and reliability of 3D soft-tissue analysis using 3D stereophotogrammetry. *Int J Oral Maxillofac Surg* 2009; 38: 267-73.
13. Powers SK, Howley ET. *Exercise physiology: Theory and application to fitness and performance*. 3th Ed. Boston: McGraw-Hill, 1996.
14. Zhao JM, Ji LL, Han MQ, Mou QN, Chu G, Chen T, et al. Lip morphology estimation models based on three-dimensional images in a modern adult population from China. *Int J Legal Med* 2021; 135: 1887-901.
15. Smith OAM, Nashed YSG, Duncan C, Pears N, Profico A, O'Higgins P. 3D Modeling of craniofacial ontogeny and sexual dimorphism in children. *Anat Rec (Hoboken)* 2021; 304: 1918-26.
16. Liu Y, Kau CH, Pan F, Zhou H, Zhang Q, Zacharopoulos GV. A 3-dimensional anthropometric evaluation of facial morphology among Chinese and Greek population. *J Craniofac Surg* 2013; 24: e353-8.
17. Kaur M, Garg RK, Singla S. Analysis of facial soft tissue changes with aging and their effects on facial morphology: A forensic perspective. *Egypt J Forensic Sci* 2015; 5: 46-56.
18. Wilkinson C. *Forensic facial reconstruction*. Cambridge: Cambridge University Press; 2004.
19. Nilendu D. Mid-sagittal Facial Soft Tissue Depth and Angular Facial Height—A Comprehensive Study. *Forensic Imaging* 2020; 20: 200355.
20. Hernández EL, Alvarez A, Abou-Ayash S, Att W. Effect of Complete Dentures on Facial Soft Tissue Volume: A 3D Comparative Study. *Int J Prosthodont* 2021; 35: 208-18.
21. Ferrario VF, Sforza C, Serrao G, Ciusa V, Dellavia C. Growth and aging of facial soft tissues: A computerized three-dimensional mesh diagram analysis. *Clin Anat* 2003; 16: 420-33.
22. Cheung LK, Chan YM, Jayaratne YS, Lo J. Three-dimensional cephalometric norms of Chinese adults in Hong Kong with balanced facial profile. *Oral Surg Oral Med Oral Pathol Oral Radiol Endod* 2011; 112: e56-e73.
23. Packiriswamy V, Kumar P, Rao M. Identification of facial shape by applying golden ratio to the facial measurements: an interracial study in malaysian population. *N Am J Med Sci* 2012; 4: 624-9.
24. Farkas LG, Katic MJ, Forrest CR, Alt KW, Bagic I, Baltadjiev G, et al. International anthropometric study of facial morphology in various ethnic groups/races. *J Craniofac Surg* 2005; 16: 615-46.
25. Bravo-Hammett S, Nucci L, Christou T, Aristizabal JF, Kau CH. 3D Analysis of Facial Morphology of a Colombian Population Compared to Adult Caucasians. *Eur J Dent* 2020; 14: 342-51.